

## **ASSESSMENT OF COMPLICATIONS OCCURRING AFTER THIRD MOLAR REMOVAL IN SPECIALIZED DENTAL CENTRE, KFH, MEDINA, KSA: A RETROSPECTIVE STUDY**

*Abdulmoeen E. Alhejali, Mohammed W. Alharbi, Ali S. Alshehri, Ahmed E. Alhejaili & Abdulrahman H. Alsaadi*

*Research Scholar, Specialized Dental Centre, KFH, Medina, KSA*

### **ABSTRACT**

*The wisdom teeth, or third molars, usually erupt between the ages of 17 and 26. The area available for eruption of these molars may be limited because they are the final teeth to erupt. This frequently results in a partial eruption or a complete lack of eruption. In most situations, failure eruption occurs when second molars physically hinder complete eruption by interfering with the eruption path*

### **Methods**

*This retrospective cross-sectional study included 400 patients had been selected randomly among the population treated in Specialized Dental Centre, KFH, Medina, KSA, between January 2017 and August 2021. The demographics of the patients as well as the radiological parameters using plain film radiography of each case were recorded.*

### **Results**

*A total of 400 third molars were extracted under local anesthesia in 183 men and 217 women, mean age 25.2 years (range 16-36). Extractions were performed by senior (n=300) and junior (n=100) surgeons who used the same standard operative technique for all patients.*

### **Conclusion**

*Patients treated by both junior and senior surgeons had postoperative problems. However, the findings of this study reveal that when patients are treated by less experienced surgeons, there is a statistically significant greater incidence of problems in various parameters following third molar removal. Trismus, sore throat, delayed healing, infection, alveolar osteitis, and nerve paraesthesia were all found to be associated with these results.*

**KEYWORDS:** *Wisdom Teeth, Specialized Dental Centre*

---

### **Article History**

**Received: 11 Dec 2021 | Revised: 24 Dec 2021 | Accepted: 24 Dec 2021**

---

### **INTRODUCTION**

The wisdom teeth, or third molars, usually erupt between the ages of 17 and 26. The area available for eruption of these molars may be limited because they are the final teeth to erupt. This frequently results in a partial eruption or a complete lack of eruption. In most situations, failure eruption occurs when second molars physically hinder complete eruption by interfering with the eruption path. Pathological alterations such as pericoronitis, dental caries, damage of surrounding

structures, cysts, and tumours have been linked to impacted third molars<sup>1</sup>. The overall complication rate is low, and the majority of the issues are minor. Nonetheless, third molar extraction is so common that complications are likely to be numerous. Limiting intraoperative or postoperative complications may have a significant impact on patient outcomes. The extraction of third molars is one of the most common dental treatments in individuals aged 16 to 21 years. Pain, edema, dysphagia, and infection are the most common side effects of these treatments.<sup>2-3</sup> This raises questions regarding the wisdom of removing third teeth prophylactically. Recurrent pericoronitis, an unfavourable eruption trajectory and the prevention of tooth crowding, periodontal deterioration, and the development of pathology<sup>4-5</sup> are the most common reasons for removal.

The most commonly impacted teeth are the third molars, which may fail to erupt into a normal functional position. In different populations, the prevalence of impacted third molars varies from 16.7% to 68.6%. According to studies from the Gulf region, 32–40.5 % of third molars are impacted.<sup>8,9</sup> According to a recent study from Oman, 54.3 % of young Omani adults aged 19 to 26 have at least one impacted third molar. The extraction of third molars is one of the most common dental surgery procedures<sup>4</sup> The majority of third molar surgeries go off without a hitch during or after the treatment, but this frequent procedure can occasionally result in a slew of complications. Sensory nerve injury, dry socket, infection, bleeding, and discomfort are the most prevalent consequences following third molar surgery. Severe trismus, iatrogenic damage to the adjacent second molar, and iatrogenic mandibular fracture are less common consequences. Preoperative planning and the integration of surgical technique with surgical principles are critical in all surgical procedures to reduce the risk of complications<sup>5</sup>. Third molar extraction complications range from 4.6 % to 30.9 %, and they might occur during the procedure or develop later. Before surgery, the surgeon must advise the patient about the statistical likelihood of problems so that the patient can make an informed decision about whether or not to proceed with the procedure<sup>6</sup>. Any issue should be managed by the surgeon in a timely and corrective way<sup>7</sup>

The most recent assessment of third molar impactions in Saudi Arabia was published more than 30 years ago. However, there have been no articles recently that explore this topic, especially none that focus on Saudi Arabia's Western region. The goal of this study is to document the present occurrence pattern of third molar impactions, as well as the reasons for extraction, in a sample of people living in Riyadh, Saudi Arabia.<sup>8</sup>

We believe that the primary motivation for extraction is personal preference. The findings of this study can aid in the gathering of more relevant data on a variety of factors, including gender, age, systemic disease, number of areas and angulation, and pathological incidence.

## **METHOD**

This retrospective cross-sectional study included 400 patients had been selected randomly among the population treated in Specialized Dental Centre, KFH, Medina, KSA, between January 2017 and August 2021. The demographics of the patients as well as the radiological parameters using plain film radiography of each case were recorded. The teeth were categorized as fully erupted, totally impacted (i.e. unerupted), or moderately affected (i.e. partially impacted) (ie partially erupted). Proforma were used to collect data. 400 hundred proform as were chosen at random and assessed by an impartial assessor to verify data input quality. The data was analyzed using the Statistical Package for Social Scientists (SPSS version 18.0).

Outcomes were summarized as frequencies according to the surgeon's grade when the procedure was performed. The chi-square test was employed to analyze the data.

## **RESULT**

A total of 400 third molars were extracted under local anesthesia in 183 men and 217 women, mean age 25.2 years (range 16-36). Extractions were performed by senior (n=300) and junior (n=100) surgeons who used the same standard operative technique for all patients.

In the group of patients treated by juniors, there was a higher frequency of postoperative problems and a statistically significant difference. \* Trismus (p=0.001), \* sore throat (p = 0.004), \*delayed healing (p = 0.009), \*alveolar osteitis (p=0.001), and \*postoperative infection (p=0.001) were among them. The only consequence identified to have a significantly higher incidence in the group of patients treated by seniors (p=0.001) was \*postoperative hemorrhage. In terms of postoperative edema and abscess, there were no statistically significant differences in either group. Within the first month after surgery, individuals treated by juniors were nearly 20 times more likely to develop inferior alveolar and lingual nerve paraesthesia. \* (p= 0.001).

## **DISCUSSION**

Third molar extraction is one of the most common procedures in the field of dento-alveolar surgery, and the prevalence of postoperative complications is generally minimal. As a result, trainees have several opportunities to learn how to do third molar surgery properly and safely. The findings imply that these activities are not difficult to master, but that they do require experience to minimize negative outcomes.<sup>9-10</sup>

Previous training programs provided a wide spectrum of surgical experience in a variety of specialties. Some general surgical principles are best learnt by direct observation and/or aiding older colleagues, building on information learned via textual learning materials.<sup>10-12</sup> Although the present trend of minimal access surgery is admirable, in tough or complicated instances, a shift to a wider or alternate exposure should be taught as the default position. Surgical exposure improves surgeons' ability to avoid overly severe instrumentation of the oral cavity (through a small incision) and reduces the necessity for considerable mouth opening, which has its own set of risks. Junior surgeons may have a tougher time recognizing complex cases that require a different strategy at first. Previous research has revealed that a surgeon's experience may influence the occurrence of problems. This could be due to a surgeon's ability to analyze and plan treatment, which improves with experience. Potential complications should be identified by surgeons, who should try to avoid or minimize them.<sup>12-13</sup>

Third molar extraction complications are not rare in dental and maxillofacial surgical operations. Minor inflammatory reactions such as discomfort and swelling to nerve damage, mandibular fracture, and serious life-threatening infections are all possible complications.<sup>14-15</sup> The overall intraoperative and postoperative complication rates in the current study were 3.7 % and 8.3 %, respectively. In terms of general patient health, the majority of reported problems were minor and temporary. These complication rates were within the literature's quoted ranges. The majority of research focused on postoperative complication rates rather than intraoperative complication rates. Azenha et al. found a 10.4 % overall complication rate, whereas Bui et al. and Muhonen et al. found 9.8 % and 9.1 % postoperative complication rates, respectively.<sup>12,16,17,18</sup>

The current study discovered that difficulties connected with mandibular third molar extraction were more common than complications associated with maxillary third molar extraction. 79 (80.6 %) of the 98 problems were linked to the mandibular third molars. The majority of investigations on third molar ectomy issues have come up with similar results.<sup>12-15</sup>

In the current investigation, clinically significant intraoperative bleeding occurred in eight patients (0.7%), which is close to the reported range of 0.2–5.8%. 11 Unexpected bleeding was shown to be common in 0.6 % of cases by Bui et al., and 0.7 % in an American age-related third molar research.<sup>12,13</sup> The disparity in reported bleeding rates could be attributable to different definitions and conditions for calculating haemorrhage.

Six occurrences of tuberosity fracture were discovered in the current investigation, all of which were treated conservatively. Primary closure was used to treat six cases of soft tissue injury caused by tears of the adjacent oral mucosal tissue. In two of the cases, iatrogenic injury to an adjacent tooth occurred; in one of the cases, the coronal restoration of an adjacent tooth was shattered. When teeth with extensive restorations or carious lesions are elevated, they are at risk of breakage or injury (rate: 0.3–0.4%).<sup>19-20</sup> The neighbouring second molar was luxated from its socket, which was relocated and stabilised in the second incidence of iatrogenic injury. It was discovered that it had good stability during follow-up and that no further treatment was required. Furthermore, there was no statistically significant link between intraoperative problems and postoperative complications in any of the cases.

Dry socket, infection, haemorrhage, and sensory problems due to nerve damage are the most commonly documented postoperative complications of third molar removal in the literature.<sup>11-23</sup> The overall postoperative complication rate in this study was 8.3 %. Extraction of third molars is frequently associated with expected and typically transient postoperative pain, swelling, and trismus..

Injury to the IAN and LN is a well-known complication of third molar extraction. Both patients and surgeons are concerned about this type of injury, which can result in significant morbidity and lawsuit.<sup>22</sup> Previous research has found a wide range of frequencies of LN and IAN injuries (0–23% and 0.4–8.1%, respectively).<sup>12,15,22,23</sup> The LN and IAN injury rates in this trial were 5.6 % and 1.6 %, respectively. Patients with LN damage typically lose sensation on the affected side of the tongue. Kiesselbach and Chamberlain discovered that the site of LN was very inconsistent in a cadaveric investigation, leaving patients prone to injury during the surgery (i.e., during incision, mucoperiosteal flap elevation, lingual flap retraction, tooth sectioning, tooth extraction and suturing).<sup>24-28</sup>

There are some limitations to this study. Third molar extractions under general anesthesia were not included; inclusion of these instances would have resulted in a larger sample size and more detailed complication data. Furthermore, because this was a retrospective analysis, there were occasions where data was limited or absent. If information on the anatomic and radiographic placements of teeth, the position of the IAN, indications for removal, social history, including smoking, surgical difficulties, and surgeon experience had been provided, a more complete data set could have helped analyse consequences more precisely. This insufficiency underlines the need for more extensive record keeping and future research that should include more criteria, such as risk variables that can influence treatment result; this could assist to reduce third molar extraction difficulties.

## CONCLUSION

Patients treated by both junior and senior surgeons had postoperative problems. However, the findings of this study reveal that when patients are treated by less experienced surgeons, there is a statistically significant greater incidence of problems in various parameters following third molar removal. Trismus, sore throat, delayed healing, infection, alveolar osteitis, and nerve paraesthesia were all found to be associated with these results.

More research into the factors that influence problems and how to avoid them is required. Even if OMFS residents are tightly supervised, it is hard to minimize the issues described in this study because all doctors gain experience. Complications do arise in individuals treated by more senior surgeons, according to this study.

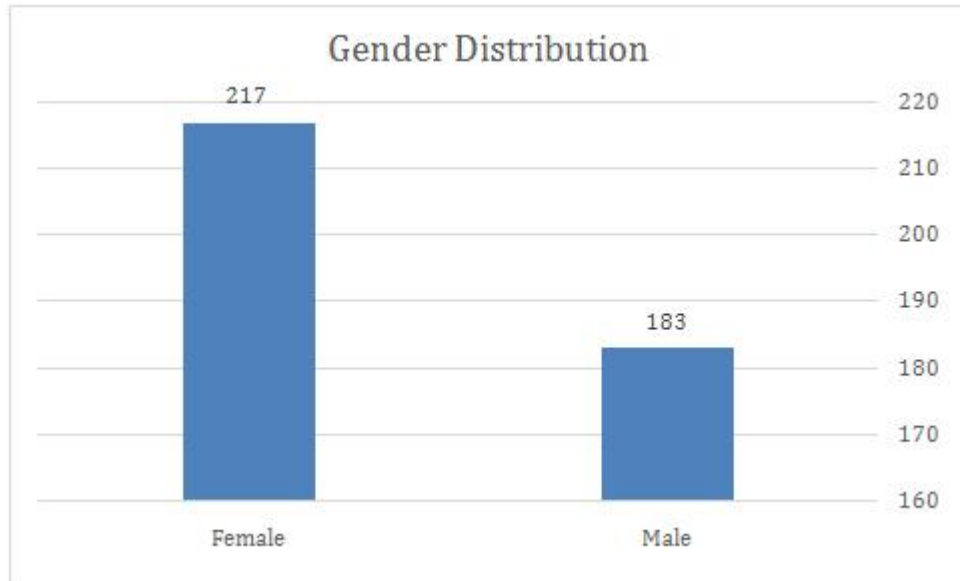
## REFERENCES

1. Miloro M, Ghali GE, Larsen PE, Waite PD. *Peterson's Principles of Oral and Maxillofacial Surgery*. 2nd ed. London: BC Decker Inc; 2004. p. 139.
2. Brown LH, Berkman S, Cohen D, Kaplan AL, Rosenberg M. A radiological study of the frequency and distribution of impacted teeth. *J Dent Assoc S Afr*. 1982;37:627–30.
3. Fanning EA, Moorrees CF. A comparison of permanent mandibular molar formation in Australian Aborigines and Caucasoids. *Arch Oral Biol*. 1969;14:999–1006. doi: 10.1016/0003-9969(69)90069-7.
4. Hugosan A, Kugelberg CF. The prevalence of third molars in a Swedish population. An epidemiological study. *Community Dent Health*. 1988;5:121–38.
5. Hashemipour MA, Tahmasbi-Arashlow MT, Fahimi-Hanzaei FF. Incidence of impacted mandibular and maxillary third molars: A radiographic study in Southeast Iran population. *Med Oral Patol Oral Cir Bucal*. 2013;18:e140–5. doi: 10.4317/medoral.18028.
6. Kaya GS, Aslan M, Ömezil MM, Dayı E. Some morphological features related to mandibular third molar impaction. *J Clin Exp Dent*. 2010;2:12–17. doi: 10.4317/jced.2.e12.
7. Hattab FN, Rawashdeh MA, Fahmy MS. Impaction status of third molars in Jordanian students. *Oral Surg Oral Med Oral Pathol Oral Radiol Endod*. 1995;79:24–9. doi: 10.1016/S1079-2104(05)80068-X.
8. Haidar Z, Shalhoub SY. The incidence of impacted wisdom teeth in a Saudi community. *Int J Oral Maxillofac Surg*. 1986;15:569–71. doi: 10.1016/S0300-9785(86)80060-6.
9. Hassan AH. Pattern of third molar impaction in a Saudi population. *Clin Cosmet Investig Dent*. 2010;2:109–13. doi: 10.2147/cciden.s12394.
10. Al-Anqudi SM, Al-Sudairy S, Al-Hosni A, Al-Maniri A. Prevalence and pattern of third molar impaction: A retrospective study of radiographs in Oman. *Sultan Qaboos Univ Med J*. 2014;14:e388–92.
11. Bouloux GF, Steed MB, Perciaccante VJ. Complications of third molar surgery. *Oral Maxillofac Surg Clin North Am*. 2007;19:117–28. doi: 10.1016/j.coms.2006.11.013.
12. Bui CH, Seldin EB, Dodson TB. Types, frequencies, and risk factors for complications after third molar extraction. *J Oral Maxillofac Surg*. 2003;61:1379–89. doi: 10.1016/j.joms.2003.04.001.

13. Chiapasco M, De Cicco L, Marrone G. Side effects and complications associated with third molar surgery. *Oral Surg Oral Med Oral Pathol.* 1993;76:412–20. doi: 10.1016/0030-4220(93)90005-o.
14. Haug RH, Perrott DH, Gonzalez ML, Talwar RM. The American Association of Oral and Maxillofacial Surgeons age-related third molar study. *J Oral Maxillofac Surg.* 2005;63:1106–14. doi: 10.1016/j.joms.2005.04.022.
15. Sisk AL, Hammer WB, Shelton DW, Joy ED., Jr Complications following removal of impacted third molars: The role of the experience of the surgeon. *J Oral Maxillofac Surg.* 1986;44:855–9. doi: 10.1016/0278-2391(86)90221-1.
16. Brauer HU. Unusual complications associated with third molar surgery: A systematic review. *Quintessence Int.* 2009;40:565–72.
17. Azenha MR, Kato RB, Bueno RB, Neto PJ, Ribeiro MC. Accidents and complications associated to third molar surgeries performed by dentistry students. *Oral Maxillofac Surg.* 2014;18:459–64. doi: 10.1007/s10006-013-0439-9.
18. Muhonen A, Ventä I, Ylipaavalniemi P. Factors predisposing to postoperative complications related to wisdom tooth surgery among university students. *J Am Coll Health.* 1997;46:39–42. doi: 10.1080/07448489709595585.
19. Blum IR. Contemporary views on dry socket (alveolar osteitis): A clinical appraisal of standardization, aetiopathogenesis and management: A critical review. *Int J Oral Maxillofac Surg.* 2002;31:309–17. doi: 10.1054/ijom.2002.0263.
20. Garcia AG, Grana PM, Sampedro FG, Diago MP, Rey JM. Does oral contraceptive use affect the incidence of complications after extraction of a mandibular third molar? *Br Dent J.* 2003;194:453–5. doi: 10.1038/sj.bdj.4810032.
21. Alexander RE. Dental extraction wound management: A case against medicating postextraction sockets. *J Oral Maxillofac Surg.* 2000;58:538–51. doi: 10.1016/S0278-2391(00)90017-x.
22. Jerjes W, Upile T, Shah P, Nhembe F, Gudka D, Kafas P, et al. Risk factors associated with injury to the inferior alveolar and lingual nerves following third molar surgery-revisited. *Oral Surg Oral Med Oral Pathol Oral Radiol Endod.* 2010;109:335–45. doi: 10.1016/j.tripleo.2009.10.010.
23. Middlehurst RJ, Barker GR, Rood JP. Postoperative morbidity with mandibular third molar surgery: A comparison of two techniques. *J Oral Maxillofac Surg.* 1988;46:474–6. doi: 10.1016/0278-2391(88)90415-6.
24. Kiesselbach JE, Chamberlain JG. Clinical and anatomic observations on the relationship of the lingual nerve to the mandibular third molar region. *J Oral Maxillofac Surg.* 1984;42:565–7. doi: 10.1016/0278-2391(95)90631-2.
25. Carmichael FA, McGowan DA. Incidence of nerve damage following third molar removal: A west of Scotland oral surgery research group study. *Br J Oral Maxillofac Surg.* 1992;30:78–82. doi: 10.1016/0266-4356(92)90074-S.
26. Rood JP. Permanent damage to inferior alveolar and lingual nerves during the removal of impacted mandibular third molars. Comparison of two methods of bone removal. *Br Dent J.* 1992;172:108–10. doi: 10.1038/sj.bdj.4807777.

- 27. Brann CR, Brickley MR, Shepherd JP. Factors influencing nerve damage during lower third molar surgery. *Br Dent J.* 1999;186:514–16. doi: 10.1038/sj.bdj.4800155.
- 28. Costantinides F, Biasotto M, Maglione M, Di Lenarda R. Local vs general anaesthesia in the development of neurosensory disturbances after mandibular third molars extraction: A retrospective study of 534 cases. *Med Oral Patol Oral Cir Bucal.* 2016;21:e724–30. doi: 10.4317/medoral.21238

**FIGURE**



**Figure 1**

